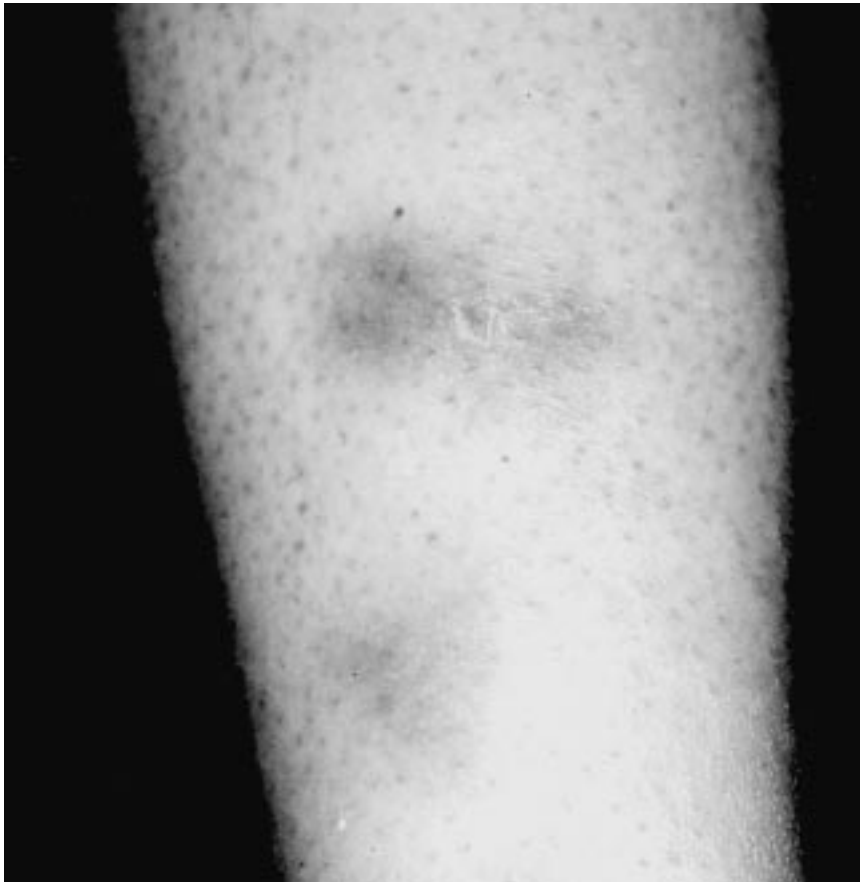


Dermatology

Notes

Erythema Nodosum



A SEPTAL PANNICULITIS results in this disorder, which has been attributed to inflammatory bowel disease, sarcoidosis, tuberculosis, and other infections, Behçet's disease, numerous drugs, and pregnancy.

—*Albert M. Lefkovits, M.D., Marsha Gordon, M.D., and Mark Lebwohl, M.D.*