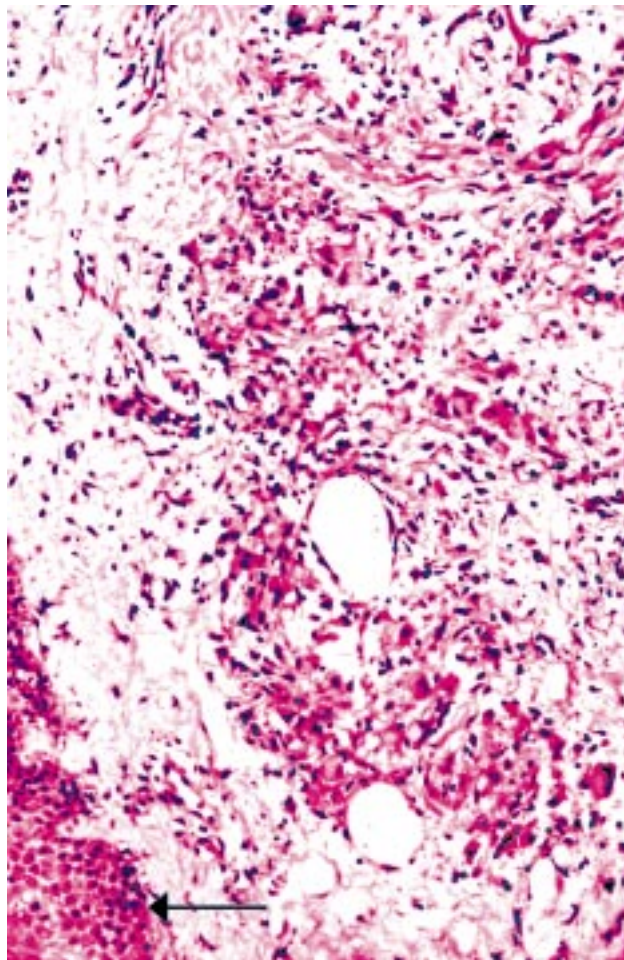


Metastatic Crohn's Disease



METASTATIC CROHN'S DISEASE is characterized by noncaseating granulomas in skin lesions that are remote from the gastrointestinal tract. The arrow marks the epidermis. (Hematoxylin and eosin-100X)

—Robert Phelps, M.D., and Mark G. Lebwohl, M.D.