

## Restenosis and Drug-Eluting Stents

ROBERT D. WINSLOW, M.D., SAMIN K. SHARMA, M.D., AND MICHAEL C. KIM, M.D.

### Abstract

The implantation of intracoronary stents for the treatment of coronary atherosclerotic disease is one of the most common percutaneous procedures. While the procedure brings long-term benefit for a large percentage of patients, a significant number of patients experience in-stent restenosis (ISR). ISR may be caused by a number of biological and procedural factors, including lesion characteristics as well as co-existing disease states like diabetes. Many strategies have been developed to try to reduce the incidence of ISR. The primary methods include systemic pharmacologic treatments, as well as attempts at modifying stents to reduce their role in the development of ISR. Drug-eluting stents are one such modality, and are expected to become a widely used tool in the field of interventional cardiology. This review will focus on the pathophysiology of ISR and possible ways to prevent it, including drug-eluting stents.

**Key Words:** Restenosis, drug-eluting stents, review.

### Introduction

THE TREATMENT OF CORONARY ARTERY DISEASE remains one of the paramount problems in cardiology. In the year 2000, there were 1,025,000 percutaneous transluminal coronary procedures performed in the US, of which 456,000 included the placement of intracoronary stents (1). Stenting is rapidly becoming the preferred method for the percutaneous treatment of coronary artery disease, since it has distinct advantages over angioplasty alone. For example, stents prevent acute vessel closure and early vessel recoil, and improve the long-term patency of vessels. Rates of restenosis in a stented vessel are reported to be as low as 20% and as high as 40%, which is about half that of percutaneous transluminal coronary angioplasty (PTCA) alone (2–5).

One of the major risk factors for restenosis is diabetes, which doubles the incidence when com-

pared to non-diabetic patients (6, 7). Other risk factors include the length of the stented segment and the size of the vessel, with smaller vessels having a higher rate of restenosis (8). There are other characteristics of the vessel itself that contribute to restenosis. Vessels that have undergone remodeling, as defined by intravascular ultrasound (vessel cross-sectional area at the lesion being greater than non-diseased segments), have a higher rate of restenosis, by at least 50%, after both PTCA and stenting (9, 10). There are also poorly understood patient factors that influence both the rate of progression of untreated lesions and restenosis, since patients who get restenosis of treated segments are more likely to have progression of other untreated diseased segments over the same time period (7). Other factors that contribute to the likelihood of restenosis include the amount of damage to the vessel wall during the procedure (11, 12) and the design of the stent itself (13–16).

### In-Stent Restenosis

The pathophysiology of in-stent restenosis (ISR) has been well described. It is primarily due to hyperplasia of smooth muscle cells in the intimal layer of the vessel wall (so-called neointimal hyperplasia) and, to a much lesser extent, mural thrombus (17–22). On the molecular and cellular

---

From the Zena and Michael A. Wiener Cardiovascular Institute and The Marie-Josée and Henry R. Kravis Center for Cardiovascular Health, Mount Sinai Medical Center, New York, NY.

Address all correspondence to Samin K. Sharma, M.D., Cardiovascular Institute, Box 1030, Mount Sinai Medical Center, New York, NY 10029.

Adapted from a Grand Rounds presentation to the Department of Medicine, Mount Sinai School of Medicine, New York, NY on October 17, 2003, and updated as of May 2004.

levels, the initial insult is vascular injury caused by both inflation of intracoronary balloons and the metal of the stent itself (23–25). This causes both macrophages and polymorphonuclear neutrophils to migrate to the site of damage, where they release chemokines (19, 21, 26). These chemokines serve to increase the amount of matrix metalloproteinase, which leads to remodeling of the extracellular matrix and smooth muscle cell migration (27, 28). Smooth muscle cells are also stimulated to increase the expression of genes involved in cell division (29). It is both the interaction and the extent of these processes that lead to neointimal hyperplasia and ISR. Compared to restenosis after PTCA, the pathophysiology of ISR may be different. Histologic examination of atherectomy specimens shows a more cellular and proliferative response in ISR than in restenosis after PTCA (30). Stenting also raises the systemic levels of inflammatory markers such as C-reactive protein and interleukin-6 (31).

### Efforts to Reduce ISR

Various methods have been employed in the animal lab, as well as the clinical setting and catheterization lab to decrease the incidence of ISR. These methods include systemic administration of drugs, administration of radiation, and coating of stents with a variety of elements, compounds and drugs.

#### Systemic Administration of Drugs

Some of the first attempts to decrease ISR involved the use of systemic medications that were active against platelet and thrombus formation. While there are some data suggesting that inhibition of thrombus formation decreases neointimal hyperplasia (32), the results in clinical trials using such agents as ticlopidine and aspirin (ISAR trial) (33) and abciximab (ERASER trial) (34) have not shown a decrease in the incidence of ISR. The FLARE trial was designed to test the effects of a statin (fluvastatin) on ISR; it had little effect (35).

One of the more interesting attempts to control ISR is by the administration of systemic glucocorticoids to decrease inflammation and neointimal hyperplasia. A study by Lee et al. randomized patients to a single dose of methylprednisolone prior to stenting. At follow-up angiography, the rates of ISR were 17.5% in the steroid group, vs. 18.8% in the control group (36). The recently published IMPRESS trial took patients with elevated C-reactive protein levels 72 hours after stenting, and randomized them to receive 45 days of prednisone vs.

placebo. The group that received prednisone had both a lower event rate as well as lower ISR (7% prednisone, 33% placebo) (37). This evidence suggests that patients with prolonged, active inflammation after stenting derive a benefit from systemic immunosuppression, and that inflammation plays a clinical role in neointimal hyperplasia.

Systemic antiproliferative agents have been studied sparingly in animal models. Everolimus, a macrolide antibiotic similar to rapamycin, was given to rabbits both before stenting and for one month after the procedure to study its effects on ISR. The groups receiving active drug had an approximately 45% reduction in neointimal thickness, but significant systemic side effects, mostly gastrointestinal. Histologic examination of arterial specimens demonstrated more healing of the endothelium and intimal wall than studies using coated stents (38).

While some systemic treatments show promise, early experiences did not demonstrate significant reduction in the rate of ISR. The concentrations of medicines at the site of pathology in the coronary artery may not have been high enough, and the side effects of systemic administration may have limited appropriate dosing. This led to the theory that coating of stents with compounds or medications may allow for local delivery of a substance in a concentration high enough to disrupt the restenotic process.

#### Principles of Coated Stents

Stents are made primarily from surgical-grade stainless steel. The first generation of coated stents added an element such as carbon or gold to the stent surface to give it different properties. The next generation of coatings consisted of polymers that could be used primarily as reservoirs for other drugs or substances. These matrices enabled the coating to be durable, uniform and able to reliably deliver doses, while controlling the kinetics of delivery. And they enable drugs to elute into the surrounding tissue over time frames of approximately one month (39–41). After the initial studies of these polymer coatings in animals, it was noted that the polymers themselves could increase inflammation and neointimal hyperplasia, compared to bare metal stents (42–44). The biocompatibility of both the matrix and the drug are important in understanding the effects on the vessel wall and ISR after implantation. The coatings themselves are not always stable during expansion and sterilization, which is another factor that contributes to the effects of coated stents (45). Therefore, the coatings must be stable both when applied to a

stent and during deployment, the matrix must be biocompatible and not increase ISR by itself, and the medicine must be delivered in the correct concentrations and with the proper kinetics.

The most common drugs applied to coated stents are anticoagulants (heparin), steroids, and antiproliferative agents like paclitaxel and rapamycin (Table 1).

**TABLE 1**  
*Substances Examined as Stent Coatings*

Coating	Mechanism of Action
<b>Biocompatible</b>	
Gold	Inert and possibly anti-inflammatory
Carbon	Inert and possibly anti-inflammatory
Si Carbide	Inert and possibly less thrombogenic
PC	Organic polymer possibly less thrombogenic
<b>Drug Coatings</b>	
Anticoagulants	
Heparin	Antithrombotic and possible SMC inhibition
Antimitotic agents	
Paclitaxel	Mitotic inhibitor
Sirolimus	Immunosuppressive and SMC inhibition

Si= silicon, PC= phosphorylcholine, SMC= smooth muscle cell

### Elemental Coatings

The first element used to coat stents was carbon, under the assumption that it might present a less thrombogenic surface to the artery (46). Initial animal data had shown both safety and a trend towards a decrease in restenosis and neointimal hyperplasia at 6 weeks (47). Nonrandomized human studies using the carbon-coated stent showed a restenosis rate of 11% in intermediate risk patients (47) and of 25% in high-risk patients (48). While not randomized or controlled, these results implied a trend towards a lower rate of ISR than with uncoated stents.

There is extensive experience in coating stents with gold. Gold has long been used as an anti-inflammatory agent in rheumatoid and psoriatic arthritis. Gold is also biocompatible and resists corrosion, and is more radiopaque and easier to see with X-ray cineangiography. Initial studies using gold-coated stents showed equivalency with uncoated stents (49, 50), but there was a suggestion that in high-risk patients, there was a higher incidence of ISR (49, 50). In a randomized trial of gold-coated stents vs. uncoated controls, there was no significant difference in acute or subacute

events or in survival, on initial analysis (51). On clinical follow-up, there appeared to be an increase in adverse cardiac events as well as angiographic evidence of more ISR, in the gold-coated stent group (52, 53). When using intravascular ultrasound, neointimal tissue proliferation was detected more often in the patients with gold-coated stents than in those with bare metal stents (53, 54). Because of the discouraging results with gold-coated stents, they are no longer being aggressively pursued as a restenosis cure.

### Stents Coated with Biocompatible Materials

Several trials have considered possible reduction in ISR with stents coated with silicon carbide and phosphorylcholine. Silicon carbide is an inert semiconductor that is both biocompatible and hemocompatible (55), and it is less thrombogenic than bare metal (56). The patients in the studies looking at silicon-carbide-coated stents had a limited number of follow-up angiograms, but the rate of ISR seemed to be similar to that with uncoated stents (57).

Phosphorylcholine is a phospholipid that is found in normal cells, and theoretically might be less thrombogenic or result in less neointimal hyperplasia, by presenting the vessel wall with a familiar surface. Animal data, however, suggests that it has little effect on the development of neointimal hyperplasia and ISR (58). Human studies in patients at high risk for ISR did show a lower than expected rate (6–17%), but many patients did not have follow-up angiograms, so the true magnitude of this effect is not known (59, 60).

### Stents Coated with Anticoagulant Agents

Heparin has long been studied as a coating for metal stents, under the assumption that the heparin coating may decrease the thrombogenicity of the stent and may lead to less neointimal hyperplasia. Animal data supports the decreased thrombogenicity, but has produced conflicting data regarding its effects on ISR (61, 62). Further testing has shown that if multiple layers of heparin are used, there is less neointimal hyperplasia in an animal model of ISR (63). The MENTOR study took patients at low risk for restenosis and implanted heparin-coated stents. These stents had a rate of ISR similar to that of uncoated stents (approximately 22%) (64). Heparin-coated stents have also been studied in acute myocardial infarction, without glycoprotein IIb/IIIa antagonists or heparin as adjunctive therapy. There was no subacute thrombosis, and a 17% rate of ISR (65). The only trial randomizing patients to

heparin vs. uncoated stents had a similar rate of restenosis in both arms of the study, of approximately 30% (66). Overall, human data suggest that coating stents with heparin does decrease the rate of subacute thrombosis, but has little effect on ISR.

### Stents Coated with Antiproliferative Agents

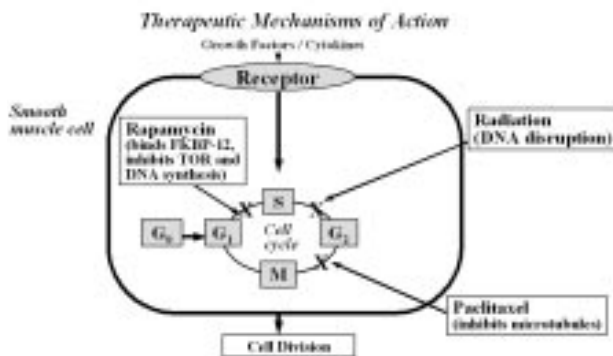
#### Paclitaxel

Paclitaxel is a derivative of taxol with antimetabolic properties. It inhibits microtubule depolymerization, and therefore arrests the cell cycle and stops proliferation. Initial data from animal studies showed a significant effect on reducing ISR when stents were coated with paclitaxel, with a decrease in the rates from 35% to 5% (67) and a difference in late luminal loss from 51(27% to 27(27% of the vessel diameter (Fig. 1; 68).

There are a number of human studies using paclitaxel-coated stents (Table 2; 69–72). The ASPECT trial randomized 177 patients to bare-metal stents, and both low- and high-dose paclitaxel-coated stents. The results of this dose-finding study showed that the high-dose-coated-stent group had a binary restenosis rate of 4% vs. 27%

for the control. The average diameter stenosis was 14% in the high-dose group and 39% in the control group (69). When the drug-coated vs. bare-metal stents were compared in an intravascular ultrasound (IVUS) substudy, the drug-coated stent group had significantly decreased neointimal hyperplasia (73). In ELUTES, 192 patients at low risk for restenosis were randomized to receive paclitaxel-coated stents at 4 different concentrations vs. the control group with bare-metal stents. There was a 3% restenosis rate in the high-dose group and a 21% rate in the control group (70). Not all trials with paclitaxel or its derivatives showed such promising results. The SCORE trial used stents coated with QP-2 (a taxane analogue similar to paclitaxel); the study was ended prematurely because of an increased risk of subacute, in-stent thrombosis. Angiographic data suggested that at 6 months the amount of neointimal proliferation was less, but the study was never completed (74).

TAXUS is a series of studies designed to look at the effectiveness of paclitaxel-coated stents on ISR. TAXUS-I randomized 30 patients to receive uncoated stents and 31 to receive paclitaxel-coated stents. The patients were at low risk for restenosis (3–3.5 mm vessels, requiring one stent), as evidenced by the 10% restenosis rate in the uncoated-stent group. The ISR rate in the paclitaxel group was 0%, but this did not achieve statistical significance. One of the only significant results of this study was a diameter stenosis at six months of  $13.6 \pm 11.8\%$  in the paclitaxel vs.  $27.2 \pm 16.7\%$  of the control stents (71). In the TAXUS-II trial, which used the same stent as TAXUS-I, 536 patients were randomized into 2 divisions, one of which was further randomized to receive a paclitaxel-coated stent with slow-release kinetics vs. uncoated stents. The other division received moderate-release paclitaxel vs. uncoated stents. All patients received aspirin and clopidogrel. The rates of ISR were approximately 20% in both control groups and 8% in both active drug groups at 6-month follow-up angiography (72). The TAXUS-III trial enrolled 28 patients, who were given up to



**Fig. 1.** Schematic of smooth muscle cell cycle, and site of action of antiproliferative agents.

FKBP = FK binding protein, TOR = target of rapamycin.

S = synthesis, G<sub>0</sub> = growth phase<sub>0</sub>, G<sub>1</sub> = growth phase<sub>1</sub>, G<sub>2</sub> = growth phase<sub>2</sub>, and M = metaphase.

**TABLE 2**  
*Randomized Trials for Primary Restenosis Using Paclitaxel*

Trial	# of Patients	ISR Risk	ISR: Control	Active
ASPECT (69)	177	NR	27%	4%
ELUTES (70)	192	Low	21%	3%
TAXUS I (71)	30	Low	10%	0%*
TAXUS II (72)	536	“Standard”	20%	6%

NR= not reported

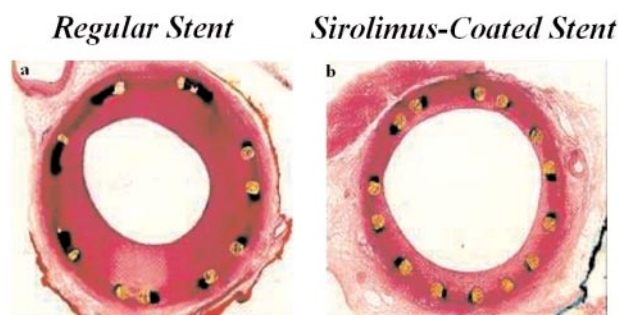
\* p=ns

2 stents for the secondary treatment of ISR, but not for primary prevention. Twenty-five of these patients had follow-up angiography. There was a 16% rate of restenosis (4 of 25), and the loss of luminal diameter was statistically greater in those who received 2 stents (75). TAXUS-IV was a large, prospective trial that compared paclitaxel-coated stents to bare-metal stents in the treatment of de novo coronary stenoses in 1,314 patients. In 559 patients who had angiography at 9 months, restenosis was reduced from 26.6% to 7.9% (76).

Despite promising early results, there is some concern about the long-term outcomes with paclitaxel-coated stents. While decreasing the rate of ISR, histologic analysis of the vessels with paclitaxel-coated stents showed less healing of the vessel wall after stenting. There was chronic low-grade inflammation, poor healing of the endothelium, and intra-intimal hemorrhage (77). In one of the only published 12-month angiographic studies, there was a 60% rate of restenosis seen at follow-up angiography. Although the sample size was small (15 patients), the suggestion is that this antiproliferative agent might only delay the onset of restenosis, or may cause late restenosis through different mechanisms, mainly delayed healing of the endothelium and vessel wall (78).

### Rapamycin

Rapamycin (sirolimus) is a macrolide antibiotic that was discovered in a microbe on Easter Island. The molecule possesses antiproliferative effects on smooth muscle cells by inhibiting growth-factor- and cytokine-induced cell division (79), a property that was noted in the early 1990s. The drug is attached to the metal of a stent, with an outer layer of biocompatible polymers that enable the drug to elute over a 30-day period (80). Initial results in animal studies showed a significant decrease (up to 50%) in ISR and amount of inflammation in lesions treated with stents coated with rapamycin (81, 82; Fig. 2).



Courtesy S. Sharma, M.

**Fig. 2.** Restenosis and drug-eluting stents. (a) Regular stent: moderate neointimal hyperplasia formation encroaching the lumen of a normal porcine coronary artery. (b) Sirolimus-coated stent: significantly less neointimal hyperplasia despite a similar degree of vessel injury.

The FIM (First in Man) study was a nonrandomized study of a rapamycin-coated stent (Table 3; 83–85). A cohort of 30 patients studied had a striking 0% ISR rate on angiography at 4 months (86, 87). Another 15-patient cohort had no ISR, and a 0% loss of diameter by IVUS at 6 months (88). In the composite of these groups, there were no adverse cardiac events over a 12-month clinical follow-up period.

The RAVEL study took 238 patients and randomized 120 to receive a rapamycin-eluting stent and 118 a bare-metal control. They were all treated with clopidogrel or ticlopidine, and only 10% of patients received a glycoprotein IIb/IIIa inhibitor. The rate of ISR was 0% in the rapamycin group and 26.6% in the control group (89). The results were validated using IVUS, and the zero restenosis rate was true for some of the higher risk patients, those with small vessels (90) and those with diabetes (83).

The results of the largest trial in rapamycin-eluting stents, the SIRIUS trial, were recently reported. The trial took 1,101 patients with de-novo

**TABLE 3**  
*Trials for Primary Restenosis Using Rapamycin*

Trial	# of Patients	ISR Risk	ISR: Control	Active
FIM (83)	45	NR	N/A	0%
RAVEL (84)	238	Moderate	27%	0%
SIRIUS (85)	1101	Moderate	35%	3%
diabetes subgroup	279	High	49%	8%

NR = not reported, N/A = not applicable

FIM = First in Man; RAVEL = RANdomized study with the sirolimus-eluting VELOCITY balloon-expandable stent in the treatment of patients with de novo native coronary artery lesions; SIRIUS = SIRolimus-coated Bx velocity balloon-expandable stent in the treatment of patients with de novo coronary artery lesions.

coronary lesions and randomized them to receive rapamycin-coated stents (556 patients) or uncoated controls (545 patients), of which 533 received coated stents and 525 bare metal stents. The rate of ISR was 35% in the control group vs. 3% in the rapamycin group at 8 months. There was a slightly higher rate of restenosis in the area immediately outside the stented segment in an additional 6%. The results were even more striking in diabetics, with an ISR rate of 49% in controls and 8% with rapamycin (85).

Rapamycin-eluting stents have also been applied to the treatment of ISR. A study by Degertekin et al. took 16 patients with ISR of 2.5–3.5 mm vessels; 4 patients had had previous brachytherapy for ISR. A total of 26 stents were placed. There was one sudden death, one late stent occlusion, and 3 instances of ISR in the 16 patients (84). These results compare favorably with those obtained with radiation therapy. However, further studies in the use of drug-eluting stents to treat ISR are needed.

### **Intracoronary Radiation Therapy**

Intracoronary radiation therapy, or brachytherapy, has been studied primarily for treatment of ISR. The initial experiences were hampered by both the need for a high dose of radiation and a high rate of edge restenosis (“candy-wrapper” effect). After these problems were addressed, many studies using various forms of radiation have shown a benefit in secondary prevention of ISR. The SCRIPPS, GAMMA-1 and WRIST trials, using gamma radiation, and PREVENT, using beta radiation, significantly decreased secondary ISR (85, 92–94). The control patients who underwent PTCA of the segment had a 50–60% rate of restenosis, while those patients who underwent PTCA and radiation therapy had a 17–32% rate, thus preventing restenosis in an additional 50–60% of cases after treatment for ISR. When the procedure consists of rotational atherectomy and radiation treatment, a 10% rate of ISR has been reported (95). Interestingly, longer follow-up angiography on patients treated with radiation shows that after a significant decrease in restenosis at 6 months, there is progressive narrowing over the next 3 months, with an additional 20% of patients meeting criteria for ISR by the 12-month mark (96).

### **Discussion**

The factors that influence vessel patency after a percutaneous procedure are numerous and com-

plex. There are a number of biological factors: co-existing diabetes, vessel size and prior remodeling. Characteristics of the procedure also play a significant role, including the amount of damage to the vessel wall, ostial lesions, and the type of stent used. Coating of stents adds additional problems: the material itself and its biocompatibility, as well as the choice of drug, its pharmacologic effects and the pharmacokinetics of its delivery. Stenting itself reduces the rate of restenosis in percutaneous procedures, but because the overall rate of primary ISR remains near 20%, there is great interest in how to decrease it. The most promising results so far have been seen with stents coated with antiproliferative compounds, with a decrease in the rate of ISR of approximately another 50–60%. Yet there is a lack of long-term follow-up, and it is possible that these agents may only delay the phenomenon, not prevent it entirely.

Other treatments show promise, as the ability to modify multiple aspects of the restenotic cascade are mapped out. For example, anti-inflammatory agents, including steroids, may help to decrease primary ISR, without specifically attacking smooth muscle cell proliferation.

The treatment of ISR poses a problem for cardiologists. Most randomized trials show that the mechanical treatment of ISR results in a 50–60% rate of secondary stenosis. Primary biologic factors are the most likely reason that patients who have ISR are at the highest risk to restenose. Neither the coating of stents with antiproliferative agents nor the addition of brachytherapy has been able to eradicate the problem of secondary stenosis.

Drug-eluting stents coated with antiproliferative agents seem to be able to prevent early ISR in the vast majority of patients who are predisposed to its development. Thus, they will probably be widely used. Nonetheless, more long-term follow-up studies are needed to determine whether this strategy actually prevents or merely delays the process. Some patients may need additional therapeutic strategies to eliminate the problem.

Drug-eluting stents also add a significant cost to the stenting procedure, with a drug-eluting stent costing approximately an extra \$2,000 (97). Restenosis impacts the cost of percutaneous interventions as well. It is estimated that the treatment of ISR costs \$8,000–\$28,000 per episode, which adds \$1,500–\$8,000 for each patient who receives a stent, regardless of whether they develop ISR (98). It seems economically viable to use drug-eluting stents for patients who need stenting, especially if only one stent is used and the patients’ risk of restenosis is high.

Because of cost issues, not all patients will be able to receive drug-eluting stents. Further research is needed to determine which subgroups will benefit most. Perhaps a formal recommendation from a national agency such as the American Heart Association or the American College of Cardiology will be of help.

### References

- Available from AHA website at [www.americanheart.org](http://www.americanheart.org) (accessed 2/7/03).
- Betriu A, Masotti M, Serra A, et al. Randomized comparison of coronary stent implantation and balloon angioplasty in the treatment of de novo coronary artery lesions (START): a four-year follow-up. *J Am Coll Cardiol* 1999; 34(5):1498–1506.
- Serruys PW, de Jaegere P, Kiemeneij F, et al. A comparison of balloon expandable stent implantation with balloon angioplasty in patients with coronary artery disease: the BENESTENT study group. *N Eng J Med* 1994; 331:489–495.
- Fischman DL, Leon MB, Baim DS, et al. A randomized comparison of coronary stent placement and balloon angioplasty in the treatment of coronary artery disease: Stent Restenosis Study Investigators. *N Eng J Med* 1994; 331:496–501.
- Mudra H, di Mario C, de Jaegere P, et al.; OPTICUS (OPTimization with ICUS to reduce stent restenosis) Study Investigators. Randomized comparison of coronary stent implantation under ultrasound or angiographic guidance to reduce stent restenosis (OPTICUS Study). *Circulation* 2001; 104(12):1343–1349.
- Lau KW, Ding ZP, Johan A, et al. Midterm angiographic outcome of single-vessel intracoronary stent placement in diabetic versus nondiabetic patients: a matched comparative study. *Am Heart J* 1998; 136(1):150–155.
- Bauriedel G, Skowasch D, Vaerst J, et al. Association between untreated coronary lesions and in-stent restenosis. *Deutsche Medizinische Wochenschrift* 2002; 127(41):2114–2119.
- Kobayashi Y, De Gregorio J, Kobayashi N, et al. Stented segment length as an independent predictor of restenosis. *J Am Coll Cardiol* 1999; 34(3):651–659.
- Okura H, Morino Y, Oshima A, et al. Pre-intervention arterial remodeling affects clinical outcome following stenting: an intravascular ultrasound study. *J Am Coll Cardiol* 2002; 37(4):1031–1035.
- Dangas G, Mintz GS, Mehran R, et al. Preinterventional arterial remodeling as an independent predictor of target lesion revascularization after nonstent coronary intervention: an analysis of 777 lesions with intravascular ultrasound imaging. *Circulation* 1999; 99(24):3149–3154.
- Karas SP, Gravanis MB, Santoian EC, et al. Coronary intimal proliferation after balloon injury and stenting in swine: an animal model of restenosis. *J Am Coll Cardiol* 1992; 20:467–474.
- Badimon JJ, Ortiz AF, Meyer B, et al. Different response to balloon angioplasty of carotid and coronary arteries: effects on acute platelet deposition and intimal thickening. *Atherosclerosis* 1998; 140(2):307–314.
- Hehrlein C, Zimmerman M, Metz J, et al. Influence of surface texture and charge on the biocompatibility of endovascular stents. *Coron Artery Dis* 1995; 6(7):581–586.
- Edelman ER, Rogers C. Stent-versus-stent equivalency trials: are some stents more equal than others? *Circulation* 1999; 100:896–898.
- Hoffmann R, Jansen C, Konig A, et al. Stent design related neointimal tissue proliferation in human coronary arteries: an intravascular ultrasound study. *Eur Heart J* 2001; 22(21):2007–2014.
- Kastrati A, Mehilli J, Dirschinger J, et al. Restenosis after coronary placement of various stent types. *Am J Cardiol* 2001; 87(1):34–39.
- Hoffmann R, Mintz GS, Dussailant GR, et al. Patterns and mechanisms of in-stent restenosis: a serial intravascular ultrasound study. *Circulation* 1996; 94:1247–1254.
- Farb A, Sangiorgi G, Carter AJ. Pathology of acute and chronic coronary stenting in humans. *Circulation* 1999; 99:44–52.
- Komatsu R, Ueda M, Naruko T, et al. Neointimal tissue response at sites of coronary stenting in humans: macroscopic, histological and immunohistochemical analyses. *Circulation* 1998; 98:224–233.
- Farb A, Weber DK, Kolodgie FD, et al. Morphological predictors of restenosis after coronary stenting in humans. *Circulation* 2002; 105:2974–2980.
- Kornowski R, Hong MK, Tio FO, et al. In-stent restenosis: contributions of inflammatory responses and arterial injury to neointimal hyperplasia. *J Am Coll Cardiol* 1998; 31:224–230.
- Mintz GS, Popma JJ, Hong MK, et al. Intravascular ultrasound to discern device-specific effects and mechanisms of restenosis. *Am J Cardiol* 1996; 78:618–622.
- Cirillo P, Golino P, Ragni M, et al. Activated platelets and leukocytes cooperatively stimulate smooth muscle cell proliferation and proto-oncogene expression via release of soluble growth factors. *Cardiovasc Res* 1999; 43(1):210–218.
- Rectenwald JE, Moldawer LL, Huber TS, et al. Direct evidence for cytokine involvement in neointimal hyperplasia. *Circulation* 2000; 102:1697–1702.
- Furukawa Y, Matsumori A, Ohashi N, et al. Anti-monocyte chemoattractant protein-1/monocyte chemoattractant and activating factor antibody inhibits neointimal hyperplasia in injured rat carotid arteries. *Circ Res* 1999; 84:306–314.
- Ott I, Neumann FJ, Kenngott S, et al. Procoagulant inflammatory responses of monocytes after direct balloon angioplasty in acute myocardial infarction. *Am J Cardiol* 1998; 82:938–942.
- Dollery CM, Humphries SE, McClelland A, et al. Expression of tissue inhibitor of matrix metalloproteinases 1 by use of an adenoviral vector inhibits smooth muscle cell migration and reduces neointimal hyperplasia in the rat model of vascular balloon injury. *Circulation* 1999; 99:3199–3205.
- Southgate KM, Fisher M, Banning AP, et al. Upregulation of basement membrane-degrading metalloproteinase secretion after balloon injury of pig carotid arteries. *Circ Res* 1996; 79:1177–1187.
- Bauters C, de Groote P, Adamantidis M, et al. Proto-oncogene expression in rabbit aorta after wall injury. First marker of the cellular process leading to restenosis after angioplasty? *Eur Heart J* 1992; 13(4):556–559.
- Moreno PR, Palacios IF, Leon MN, et al. Histopathologic comparison of human coronary in-stent and post-balloon angioplasty restenotic tissue. *Am J Cardiol* 1999; 84(4):462–466.
- Korkmaz ME, Tayfun E, Muderrisoglu H, et al. Carbon coating of stents has no effect on inflammatory response to primary stent deployment. *Angiology* 2002; 53(5):563–568.
- Unterberg C, Sandrock D, Nebendahl K, Buchwald AB. Reduced acute thrombus formation results in decreased neointimal proliferation after coronary angioplasty. *J Am Coll Cardiol* 1995; 26(6):1747–1754.
- Kastrati A, Schühlen H, Hausleiter J, et al. Restenosis after coronary stent placement and randomization to a 4-week combined antiplatelet or anticoagulant therapy: six-month angiographic follow-up of the Intracoronary Stenting and Antithrombotic Regimen (ISAR) Trial. *Circulation* 1997; 96(2):462–467.
- Ellis SG, Effron MB, Gold HK, et al. Acute platelet inhibition with abciximab does not reduce in-stent restenosis (ERASER study). *Circulation* 1999; 100:799–806.

35. Serruys PW, Foley DP, Jackson G, et al. A randomized placebo-controlled trial of fluvastatin for prevention of restenosis after successful coronary balloon angioplasty: final results of the fluvastatin angiographic restenosis (FLARE) trial. *Eur Heart J* 1999; 20:58–69.
36. Lee CW, Chae JK, Lim HY, et al. Prospective randomized trial of corticosteroids for the prevention of restenosis after intracoronary stent implantation. *Am Heart J* 1999; 138:60–63.
37. Versaci F, Gaspardone A, Tomai F, et al. Immunosuppressive therapy for the prevention of restenosis after coronary artery stent implantation (IMPRESS study). *J Am Coll Cardiol* 2002; 40(11):1935–1942.
38. Farb A, John M, Acampado E, et al. Oral everolimus inhibits in-stent neointimal growth. *Circulation* 2002; 106(18):2379–2384.
39. Dev V, Eigler N, Sheth S, et al. Kinetics of drug delivery to the arterial wall via polyurethane-coated removable nitinol stent: comparative study of two drugs. *Cathet Cardiovasc Diagn* 1995; 34(3):272–278.
40. Lambert TL, Dev V, Rechavia E, et al. Localized arterial wall drug delivery from a polymer-coated removable metallic stent. Kinetics, distribution, and bioactivity of forskolin. *Circulation* 1994; 90(2):1003–1011.
41. Nakayama Y, Ji-Youn K, Nishi S, et al. Development of high-performance stent: gelatinous photogel-coated stent that permits drug delivery and gene transfer. *J Biomed Mater Res* 2001; 57:559–566.
42. Van der Giessen WJ, Lincoff M, Schwartz R, et al. Marked inflammatory sequelae to implantation of biodegradable and non-biodegradable polymers in porcine coronary arteries. *Circulation* 1996; 94:1690–1697.
43. De Scheerder IK, Wilczek KL, Verbeken EV, et al. Biocompatibility of polymer-coated oversized metallic stents implanted in normal porcine coronary arteries. *Atherosclerosis* 1995; 114:105–114.
44. Lee SH, Szinai I, Carpenter K, et al. In-vivo biocompatibility evaluation of stents coated with a new biodegradable elastomeric and functional polymer. *Coronary Artery Disease* 2002; 13(4):237–241.
45. Grube E. Effects of stent expansion and sterilization on first generation stent coatings. *Cath Lab Digest* 2001; 9(9):52.
46. Bartorelli AL, Trabattani D, Montorsi P, et al. Aspirin alone antiplatelet regimen after intracoronary placement of the Caribostent: the ANTARES study. *Catheter Cardiovasc Interv* 2002; 55(2):150–156.
47. De Scheerder I, Szilard M, Yanming H, et al. Evaluation of the biocompatibility of two new diamond-like stent coatings (Dylyn) in a porcine coronary stent model. *J Invasive Cardiol* 2000; 12(8):389–394.
48. Antoniucci D, Valenti R, Migliorini A, et al. Clinical and angiographic outcomes following elective implantation of the Caribostent in patients at high risk of restenosis and target vessel failure. *Catheter Cardiovasc Interv* 2001; 54(4):420–426.
49. Harding SA, McKenna CJ, Flapan AD, et al. Long-term clinical safety and efficacy of NIROYAL vs. NIR intracoronary stent. *Catheter Cardiovasc Interv* 2001; 54:141–145.
50. Cremonesi A, Benit E, Carlier M, et al. Multicenter registry to evaluate the efficacy of the NIROYAL stent in de novo or restenotic coronary arteries. *J Invasive Cardiol* 2000; 12(5):225–232.
51. Kastrati A, Schomig A, Dirschinger J, et al. Increased risk of restenosis after placement of gold-coated stents: results of a randomized trial comparing gold-coated with uncoated steel in patients with coronary artery disease. *Circulation* 2000; 101(21):2478–2483.
52. Park SJ, Lee CW, Hong MK, et al. Comparison of gold-coated NIR stents with uncoated NIR stents in patients with coronary artery disease. *Am J Cardiol* 2002; 89:872–875.
53. vom Dahl J, Haager PK, Grube E, et al. Effect of gold coating of coronary stents on neointimal proliferation following stent implantation. *Am J Cardiol* 2002; 89(7):801–805.
54. Hoffmann R, Mintz GS, Haager PK, et al. Relation of stent design and stent surface material to subsequent in-stent intimal hyperplasia in coronary arteries determined by intravascular ultrasound. *Am J Cardiol* 2002; 89(12):1360–1364.
55. Monnick SH, van Boven AJ, Peels HO, et al. Silicon-carbide coated coronary stents have low platelet and leukocyte adhesion during platelet activation. *J Investig Med* 1999; 47:304–310.
56. Heublein B, Ozbek C, Pethig K. Silicon carbide-coated stents: clinical experience in coronary lesions with increased thrombotic risk. *J Endovasc Surg* 1998; 5(1):32–36.
57. Heublein B, Pethig K, Elsayed AM. Silicon carbide coating: a semiconducting hybrid design of coronary stents: a feasibility study. *J Invasive Cardiol* 1998; 10:255–262.
58. Malik N, Gunn J, Shepherd L, et al. Phosphorylcholine-coated stents in porcine coronary arteries: in vivo assessment of biocompatibility. *J Invasive Cardiol* 2001; 13(3):193–201.
59. Galli M, Sommariva L, Prati F, et al. Acute and mid-term results of phosphorylcholine coated stents in primary coronary stenting for acute myocardial infarction. *Catheter Cardiovasc Interv* 2001; 53(2):182–187.
60. Galli M, Bartorelli A, Bedogni F, et al. Italian BiodivYsio open registry (BiodivYsio PC-coated stent): study of clinical outcomes of the implant of a PC-coated coronary stent. *J Invasive Cardiol* 2000; 12(9):452–458.
61. Ahn YK, Jeong MH, Kim JW, et al. Preventative effects of the heparin-coated stent on restenosis in the porcine model. *Catheter Cardiovasc Interv* 1999;48(3):324–330.
62. De Scheerder I, Wang K, Wilczek K, et al. Experimental study of thrombogenicity and foreign body reaction induced by heparin-coated coronary stents. *Circulation*.1997; 95(6):1549–1553.
63. Matsumoto Y, Shimokawa H, Morishige K, et al. Reduction in neointimal formation with a stent coated with multiple layers of releasable heparin in porcine coronary arteries. *J Cardiovasc Pharmacol* 2002; 39:513–522.
64. Vrolix MC, Legrand VM, Reiber JH, et al. Heparin-coated Wiktor stents in human coronary arteries (MENTOR trial). MENTOR trial investigators. *Am J Cardiol* 2000;86(4):385–389.
65. Shin EK, Son JW, Sohn MS, et al. Efficacy of heparin-coated stent in early setting of acute myocardial infarction. *Catheter Cardiovasc Interv* 2001; 52:306–312.
66. Wohrle J, Al-Khayer E, Grotzinger U, et al. Comparison of the heparin coated vs. the uncoated Jostent: no influence on restenosis or clinical outcome. *Eur Heart J* 2001; 22:1808–1816.
67. Heldman AW, Cheng L, Jenkins GM, et al. Paclitaxel stent coating inhibits neointimal hyperplasia at 4 weeks in a porcine model of coronary restenosis. *Circulation* 2001; 103:2289–2295.
68. Hong MK, Kornowski R, Bramwell O, et al. Paclitaxel-coated Gianturco-Roubin II (GR II) stents reduce neointimal hyperplasia in a porcine coronary in-stent restenosis model. *Coron Artery Dis* 2001; 12:513–515.
69. Park SJ, Shim WH, Ho DS, et al. The clinical effectiveness of paclitaxel-coated coronary stents for the reduction of restenosis in the ASPECT trial (abstract). *Circulation* 2001; 104(Suppl II):II-464.
70. Gershlick AH, De Scheerder I, Chevalier B, et al. Local drug delivery to inhibit coronary artery restenosis: data from the ELUTES (Evaluation of Paclitaxel Eluting Stent) clinical trial [abstract]. *Circulation* 2001; 104(Suppl II):II-416.

71. Grube E, Silber S, Hauptmann KE, et al. TAXUS I: six- and twelve-month results from a randomized, double-blind trial on a slow-release paclitaxel-eluting stent for de novo coronary lesions. *Circulation* 2003; 107(1):38–42.
72. TAXUS II. Presented at TCT 2002. Available from: Clinical Trial Results at [www.clinicaltrialresults.com](http://www.clinicaltrialresults.com) (accessed 2/7/03).
73. Hong M, Mintz G, Lee CW, et al. Paclitaxel coating reduces in-stent intimal hyperplasia in human coronary arteries. *Circulation* 2003; 107:517–520.
74. Grube E, Hauptmann K, Colombo A, et al. SCORE trial interim safety results: despite efficacy, late stent thrombosis with the QuaDDS-QP2 stent [abstract]. *J Am Coll Cardiol* 2002; 39(Suppl A):38A.
75. Tanabe K, Serruys PW, Grube E, et al. TAXUS III Trial: in-stent restenosis treated with stent-based delivery of paclitaxel incorporated in a slow-release polymer formulation. *Circulation* 2003; 107(4):559–564.
76. Stone GW, Ellis SG, Cox DA, et al. A polymer-based, paclitaxel-eluting stent in patients with coronary artery disease. *N Engl J Med* 2004; 350(3) 221–231.
77. Farb A, Heller PF, Shroff S, et al. Pathological analysis of local delivery of Paclitaxel via a polymer-coated stent. *Circulation* 2001; 104:473–479.
78. Liistro F, Stankovics G, Di Mario C, et al. First clinical experience with a paclitaxel derivative-eluting polymer stent system implantation for in-stent restenosis: immediate and long-term clinical and angiographic outcome. *Circulation* 2002; 105(16):1883–1886.
79. Marx SO, Jayaraman T, Go LO, Marks AR. Rapamycin-FKBP inhibits cell cycle regulators of proliferation in vascular smooth muscle cells. *Circ Res* 1995; 76(3):412–417.
80. Curfman GD. Sirolimus-eluting coronary stents. *N Eng J Med* 2002; 346(23):1770–1771.
81. Suzuki T, Kopia G, Hayashi S, et al. Stent-based delivery of sirolimus reduces neointimal formation in a porcine coronary model. *Circulation* 2001; 104(10):1188–1193.
82. Klugherz BD, Llanos G, Lieuallen W, et al. Twenty-eight-day efficacy and pharmacokinetics of the sirolimus-eluting stent. *Coron Artery Dis* 2002; 13(3):183–188.
83. Serruys PW, Degertekin M, Tanabe K, et al. Intravascular ultrasound findings in the multicenter, randomized, double-blind RAVEL (RAnDomized study with the sirolimus-eluting VELOCITY balloon-expandable stent in the treatment of patients with de novo native coronary artery Lesions) trial. *Circulation* 2002; 106(7):798–803.
84. Degertekin M, Regar E, Tanabe K, et al. Sirolimus-eluting stent for treatment of complex in-stent restenosis: the first clinical experience. *J Am Coll Cardiol* 2003; 41(2):184–189.
85. Moses JW, Leon MB, Popma JJ, et al. Sirolimus-eluting stents versus standard stents in patients with stenosis in a native coronary artery. *New Engl J Med* 2003; 349(14):1315–1323.
86. Sousa JE, Costa MA, Abizaid AC, et al. Sustained suppression of neointimal proliferation by sirolimus-eluting stents: one-year angiographic and intravascular ultrasound follow-up. *Circulation* 2001; 104:2007–2011.
87. Sousa JE, Costa MA, Abizaid A, et al. Lack of neointimal proliferation after implantation of sirolimus-coated stents in human coronary arteries: a quantitative coronary angiography and three-dimensional intravascular ultrasound study. *Circulation* 2001; 103(2):192–195.
88. Rensing BJ, Vos J, Smits PC, et al. Coronary restenosis elimination with a sirolimus eluting stent. *Eur Heart J* 2001; 22:2125–2130.
89. Morice M-C, Serruys PW, Sousa JE, et al. A randomized comparison of a sirolimus-eluting stent with a standard stent for coronary revascularization. *N Eng J Med* 2002; 346:1773–1780.
90. Regar E, Serruys PW, Bode C, et al. Angiographic findings of the multicenter Randomized Study With the Sirolimus Eluting Bx Velocity Balloon-Expandable Stent (RAVEL): sirolimus-eluting stents inhibit restenosis irrespective of the vessel size. *Circulation* 2002; 106(15):1949–1956.
91. SIRIUS. Presented at TCT 2002. Available from: Clinical Trial Results at [www.clinicaltrialresults.com](http://www.clinicaltrialresults.com) (accessed 2/7/03).
92. Teirstein PS, Massullo V, Jani S, et al. Catheter-based radiotherapy to inhibit restenosis after coronary stenting. *N Eng J Med* 1997; 336(24):1697–1703.
93. Waksman R, White RL, Chan RC, et al. Intracoronary gamma-radiation therapy after angioplasty inhibits recurrence in patients with in-stent restenosis. *Circulation* 2000; 101:2165–2171.
94. Leon MB, Teirstein PS, Moses JW, et al. Localized intracoronary gamma-radiation therapy to inhibit the recurrence of restenosis after stenting. *N Eng J Med* 2001; 344:250–256.
95. Park SW, Hong MK, Moon DH, et al. Treatment of diffuse in-stent restenosis with rotational atherectomy followed by radiation therapy with a rhenium-188-mercaptoacetyl-triglycine-filled balloon. *J Am Coll Cardiol* 2001; 38:631–637.
96. Kay IP, Wardeh AJ, Kozuma K, et al. Radioactive stents delay but do not prevent in-stent neointimal hyperplasia. *Circulation* 2001; 103:14–17.
97. Available from: HHS website. [www.hhs.gov](http://www.hhs.gov) (accessed 4/4/03).
98. Cohen DJ. Economics of Restenosis. Presented at Drug Eluting Stent Summit TCT 2002. Available from: TCT website. [www.tctmd.com](http://www.tctmd.com) (accessed 2/7/03).